FAT IS RESPONSIBLE FOR AN INTRAMURAL RADIOLUCENT BAND IN THE FELINE STOMACH WALL

Hock Gan Heng, DVM, MVS, MS, Robert H. Wrigley, BVSc, MS, Susan L. Kraft, DVM, PhD, Barbara E. Powers, DVM, PhD

An intramural radiolucent band in the stomach wall can be seen on abdominal radiographs of cats without concurrent clinical gastrointestinal signs. A retrospective study of cats with normal abdominal radiographs and computed tomography (CT) was performed to determine the prevalence of this finding. This gastric radiolucent band was seen in 13 of 37 (35%) radiographs. There was no relationship between age, weight and relative obesity and the presence of this radiolucent band. Using CT, an intramural hypoattenuating layer was detected in the stomach wall of four of 15 (27%) cats. The intramural radiolucent band was visible on the radiographs in all four of those cats. This radiographic and CT finding was histologically determined to be normal fat in the gastric submucosa in one cat cadaver. *Veterinary Radiology & Ultrasound, Vol. 46, No. 1, 2005, pp 54–56.*

Key words: cats, computed tomography, intramural fat, intramural radiolucent band, radiographs, stomach.

Introduction

In radiographic examination of the normal feline stomach wall there is typically one homogeneous soft-tissue layer.[1,2] Occasionally an intramural radiolucent band has been observed within the stomach wall of some cats presenting with or without clinical signs of gastrointestinal disease (Figs. 1A and 1B). Because of the fact that this radiolucent band can be detected in cats without any gastrointestinal signs, possible explanations for this finding include intramural fat or optical illusion.[3] Mach line optical illusions have been associated with urinary bladder, bowel, and tracheal wall.[4,5] These observations prompted a study to determine the character of this radiolucent band and relationship to age, weight, and relative obesity.

Materials and Methods

Radiographic Evaluation

A retrospective study was performed of normal feline abdominal radiographs made at James L Voss Veterinary Teaching Hospital, Colorado State University from the year 2001. The inclusion criteria for this study were cats that presented without any gastrointestinal signs and had two orthogonal radiographic views (lateral and ventrodorsal) interpreted as normal. The radiographic views and the stage of fullness of the stomach in which a gastric intramural radiolucent band was visible were recorded. Relative obesity was assessed radiographically by estimating the ratio of the height of the falciform fat to the length of the first lumbar vertebra. The height of the falciform fat was measured from the tip of the liver to the skin in a line perpendicular to the skin. Statistical analysis by logistic regression was performed* to determine the influence of age, weight, and relative obesity on the presence of the gastric radiolucent band. The level of significance was set at $P = 0.05$.

Computed Tomography (CT) Evaluation

A retrospective evaluation was done of the cranial abdominal CT examinations of cats with no clinical signs of gastrointestinal disease at the James L Voss Veterinary Teaching Hospital, Colorado State University during the last 5 years (1998–2002). The CT images were scrutinized for the presence of any intramural hypoattenuating layer of the stomach wall. The Hounsfield units of the identified gastric intramural layer were measured using a cross-shape region of interest cursor. The thickness of the layer was measured using internal calipers of the CT† computer software. The CT studies were compared with radiographs from the same cats.

From the Departments of Environmental and Radiological Health Sciences (Heng, Wrigley, Kraft), Microbiology, Immunology and Pathology (Powers), College of Veterinary Medicine and Biomedical Sciences, Colorado State University, Fort Collins, CO 80523-1601.

This paper was presented at ACVR Annual Scientific Meeting 2003, December 2–6 at Chicago Marriott O'Hare Hotel, Chicago, IL, as an oral presentation.

Address correspondence and reprint requests to Hock Gan Heng, DVM, MVS, MS, at the above address. E-mail: hgheng@vet.upm.edu.my

Received January 9, 2004; accepted for publication May 28, 2004.
doi: 10.1111/j.1740-8261.2005.00010.x

*SAS software version 8, Cary, NC.
†Picker PQ 2000, Universal Medical System, Bedford Hills, NY.

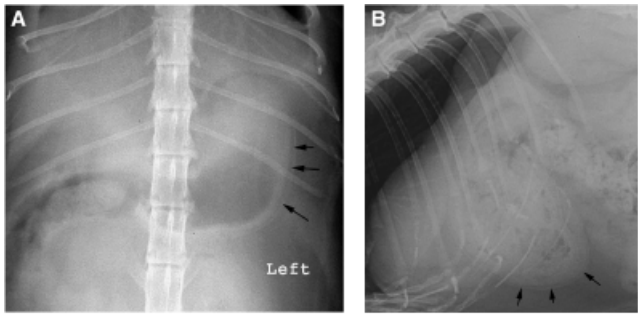

FIG. 1. (A) Close up ventrodorsal radiograph of a cat. Note the radiolucent band in the stomach wall (arrows). (B) Left lateral recumbency radiograph of a cat. Note the radiolucent band in the wall of the stomach (arrows).

Cadaver Examination

Abdominal radiographs were made of recently euthanized cats to identify a cat exhibiting an intramural radiolucent band in the gastric wall. Cranial abdominal CT examination of the stomach and histopathologic examination of the stomach wall were then performed.

Results

Radiographic Evaluation

Out of 194 feline abdominal radiographs performed in 2001, 37 cats were examined. Radiolucent bands were present in the stomach walls of 13 (35%) of these cats. The intramural radiolucent band was identified in 10 cats on the ventrodorsal view and five cats on the lateral view. The intramural radiolucent band was seen on both the ventrodorsal and lateral views in two cats. This radiolucent band was more commonly seen when the stomach was empty (eight cats) and less commonly when the stomach was ingesta-filled (five cats).

Based on the odds ratios, there is no correlation between the presence of the gastric intramural radiolucent band and age, weight, or relative obesity of the cats (Table 1).

CT Evaluation

Four of 15 cats (27%) had an intramural hypoattenuating layer between the serosa and mucosal surface of the stomach. The Hounsfield values of the hypoattenuating layers corresponded to fat, ranging from −76 to −118 with a mean of −110. The thickness of the hypoattenuating layer ranged from 1 to 2 mm. The gastric intramural radiolucent band was seen radiographically in all four cats. The intramural radiolucent band was not seen radiographically in cats that did not have an intramural hypoattenuating layer.

TABLE 1. Factors (Age, Weight and Obesity) Examined for a Relationship to the Presence of a Gastric Radiolucent Band in Cats

Factors	Cats with Radiolucent Band	Cats without Radiolucent Band	Odds Ratio
Age (year) (mean ± SD)	8.8 ± 1.2	6 ± 1	1.113
Weight (kg) (mean ± SD)	6 ± 0.4	5 ± 0.3	0.792
Relative obesity (mean ± SD)	1.2 ± 0.29	1.2 ± 0.24	1.569

Cadaver Evaluation

Seven cadavers were radiographed before identifying one with a radiolucent band in the stomach wall. In the CT images of this cat's cadaver, there was a hypoattenuating layer located between the serosa and mucosal surface. The appearance of this layer was similar to those detected in the retrospective study. The Hounsfield value of the hypoattenuating layer was −80, corresponding to fat (Fig. 2A). Histologically, there was an obvious layer of fat in the submucosa (Fig. 2B). This fat had variable thickness, with

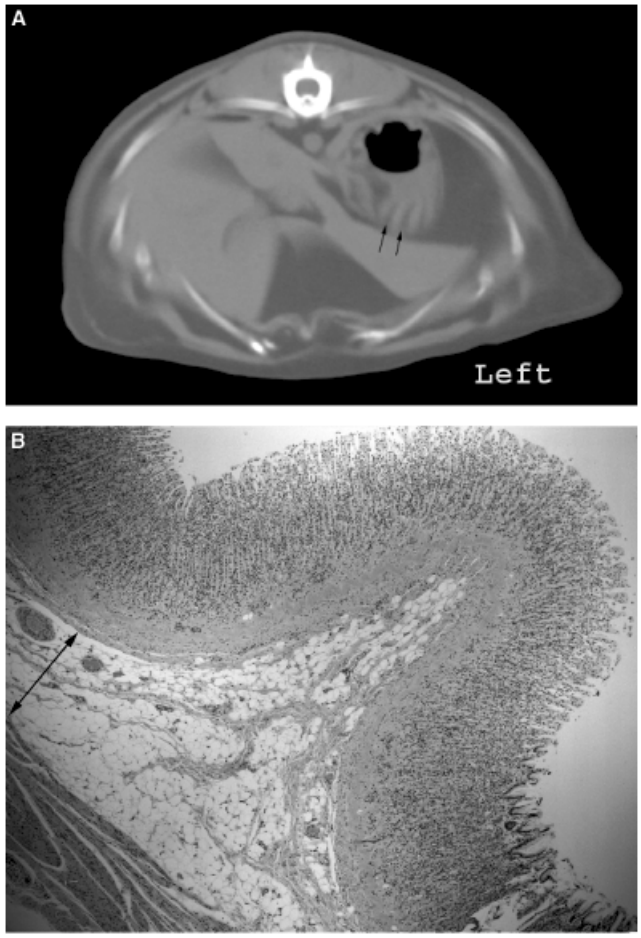

FIG. 2. (A) Computed tomography of the cranial abdomen of a cadaver. Note the fat layer between the serosa and mucosal surface of the stomach (arrows). (B) Histologic section of the stomach wall. Note the presence of thick layer of fat in the submucosa (double-headed arrow). Hematoxylin and eosin, × 40.

17408261, 2005, 1, Downloaded from https://onlinelibrary.wiley.com/doi/10.1111/j.1740-8261.2005.00010.x by LIN YI CHUN - Readcube-Labtiva , Wiley Online Library on [24/01/2026]. See the Terms and Conditions (https://onlinelibrary.wiley.com/terms-and-conditions) on Wiley Online Library for rules of use; OA articles are governed by the applicable Creative Commons License

the thickest part located in the rugal folds where they projected into the lumen of the stomach.

Discussion

The inclusion criterion was cats presenting without any gastrointestinal signs and read out as normal by the team of radiologists. This was to exclude cats with probable gastric disease. Possible differential for intramural radiolucent band is emphysematous gastritis.[6–10] The two orthogonal views were needed to compare the frequency of detecting this band on different projections.

The submucosal layer of the stomach of animals and humans consists of connective tissue containing lymphatics and nerve plexuses.[11–13] The presence of white adipose tissue in the submucosa in animals has also been described.[14] However, it was not stated in which species of animals this adipose tissue was identified. In our study, the intramural radiolucent band detected on radiographs and CT was because of intramural fat in the gastric submucosa. Although histologic examination was performed on only one cat, the Hounsfield values from other cats also supported this layer to be fat. In a report on normal CT cross-sectional anatomy of the feline abdomen, a similar intramural hypoattenuating layer is visible (see Figures 16 and 18).[15] Our findings support that this hypoattenuating layer is also probably because of fat.

There was not a significant correlation between the presence of the gastric intramural radiolucent band and age, weight, and or relative obesity of the cat. The radiolucent band in the stomach wall was best seen on ventrodorsal radiographs. This may be because of a larger surface of the stomach (body and fundus) contrasted by surrounding intraabdominal fat on this projection. On the lateral radiograph, the majority of the body and fundus of the stomach is superimposed over small bowel and liver, perhaps making visualization of the radiolucent band more difficult. Bands identified on lateral radiographs were only seen in the body of the stomach, which was surrounded by intraabdominal fat and not superimposed on any abdominal organs. These bands were seen less frequently in ingesta-filled stomachs, possibly explained by stretching and thinning of the stomach wall by the distension and superimposition of the ingesta with the stomach wall.

The limitation of this study was small sample size. Radiographic examination could only be performed on 7 cadavers with CT and histology examination of one because of limited funding. Few cats had undergone abdominal CT examination for clinical evaluation, causing the small number of patients in this category. As the band was seen in cats without clinical signs of gastrointestinal disease, biopsies of the stomach were not performed.

Conclusion

This study supports that the intramural radiolucent band and hypoattenuating layer on CT of some normal cats corresponds to fat in the gastric submucosa. This band is an incidental finding and should not be confused with gas in the stomach wall.

REFERENCES

1. Farrow CS, Green R, Shively M. Radiology of the cat. St. Louis, MO: Mosby-Year Book, 1994;139.
2. O'Brien TR. Radiographic diagnosis of the abdominal disorders in the dog and cat. Philadelphia: WB Saunders Company, 1981;204–278.
3. Papageoges M. Visual perception and radiographic interpretation. In: Thrall DE (ed): Textbook of veterinary diagnostic radiology, 4th ed. Philadelphia: WB Saunders Company, 2002;35–41.
4. Lane EJ, Proto AV, Phillips TW. Mach bands and density perception. Radiology 1976;121:9–17.
5. Edholm P. Boundaries in the radiographic image I. General principles for perception of boundaries and their application to the image. Acta Radiol Diagn 1981;22:457–473.
6. van Mook WN, van der Geest S, Goessens ML, Schoon EJ, Ramsay J. Gas within the wall of the stomach due to emphysematous gastritis: case report and review. Eur J Gastroenterol Hepatol 2002;14: 1155–1160.
7. Shipman PJ, Druru P. Emphysematous gastritis: case report and literature review. Austral Radiol 2001;45:64–66.
8. Sud A, Lehl SS, Bhasin DK, Deodhar SD. Emphysematous gastritis. Am J Gastroenterol 1996;91:604–605.
9. Heng Y, Schuffler MD, Haggitt RC, Rohrmann CA. Pneumatosis intestinalis: a review. Am J Gastroenterol 1995;90:1747–1758.
10. Burt JK. What is your diagnosis? J Am Vet Med Assoc 1982;191: 295–296.
11. Aughey E, Frye FL. Comparative veterinary histology with clinical correlates. Iowa: Iowa State University Press, 2001;107–113.
12. Banks WJ. Applied veterinary histology, 3rd ed. St. Louis, MO: Mosby Year Book, 1993;338–349.
13. Kierszenbaum AL. Histology and cell biology: an introduction to pathology. St. Louis, MO: Mosby Inc, 2002;419.
14. Frappier BL. Digestive system. In: Dellmann HD, Ecerell J (eds): Textbook of veterinary histology, 5th ed. Baltimore, MD: Williams & Wilkins, 1998;164–202.
15. Samii VF, Biller DS, Koblik PD. Normal cross-sectional anatomy of the feline thorax and abdomen: comparison of computed tomography and cadaver anatomy. Vet Radiol Ultrasound 1998;39:504–511.

17408261, 2005, 1, Downloaded from https://onlinelibrary.wiley.com/doi/10.1111/j.1740-8261.2005.00010.x by LIN YI CHUN - Readcube-Labtiva , Wiley Online Library on [24/01/2026]. See the Terms and Conditions (https://onlinelibrary.wiley.com/terms-and-conditions) on Wiley Online Library for rules of use; OA articles are governed by the applicable Creative Commons License